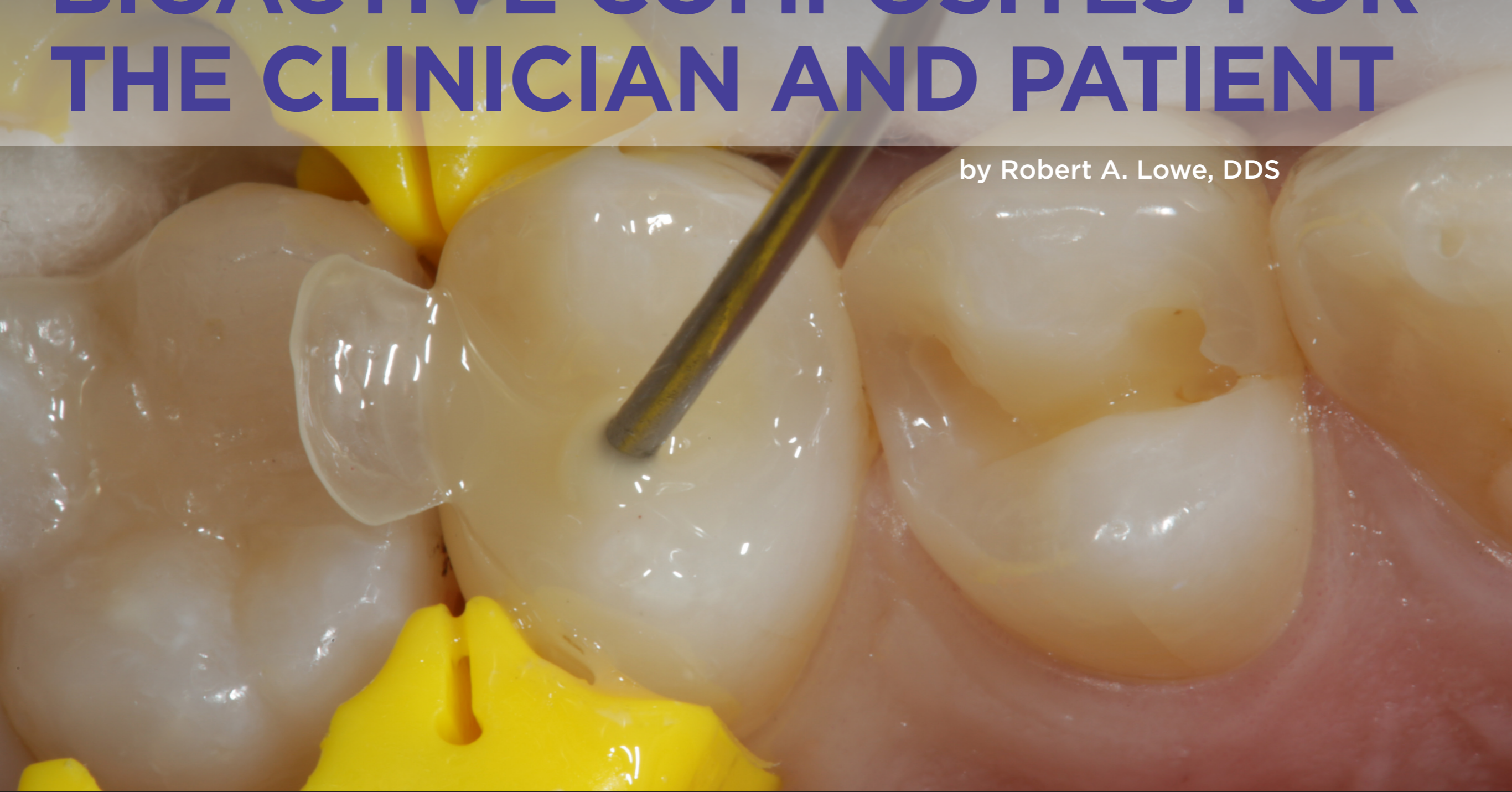

BIOACTIVE COMPOSITES FOR THE CLINICIAN AND PATIENT

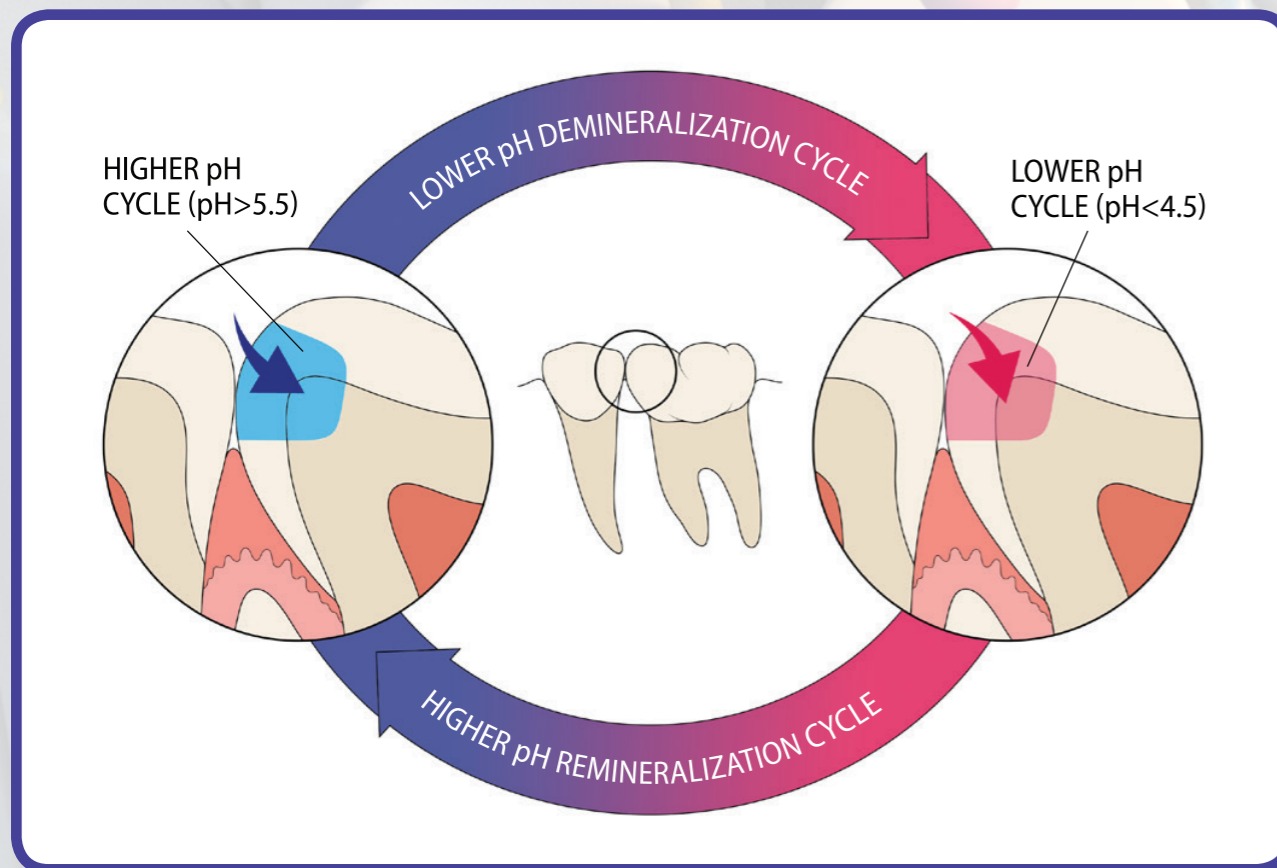
by Robert A. Lowe, DDS



Bioactive Restoratives Overview

Restorative materials are constantly under biological assault due to acid attack and the effects of demineralization on tooth structure. Clinical outcomes can vary from patient to patient due to the individual's oral environment (pH), quality and quantity of saliva, acidic challenge to the tooth-restorative interface (margin), and the patient's ability to keep these surfaces plaque free (level of home care).

Rather than actively repair teeth, the majority of today's dental restoratives are designed merely to occupy space. Bioactive restoratives, on the other hand, participate in an ionic exchange of calcium, phosphate, and fluoride that helps neutralize acid attack and supports the natural remineralization process.



Bioactive materials like **ACTIVA BioACTIVE-RESTORATIVE** respond to changes in pH by releasing and recharging essential minerals to help protect teeth against acid attack.

Bioactive Clinical Applications

Bioactive materials like **ACTIVA BioACTIVE-RESTORATIVE** can be used for a wide variety of clinical applications, including minimally invasive restorations. Figure 1 shows a micro preparation to conserve a maximum amount of tooth structure after decay was detected in the occlusal pits and grooves of teeth Nos. 29, 30, and 31. ACTIVA seals the enamel and dentin (Figure 2), protecting against microleakage. Placement is simple thanks to the precision of the metal cannula delivery system, eliminating excess and requiring minimal or no finishing.

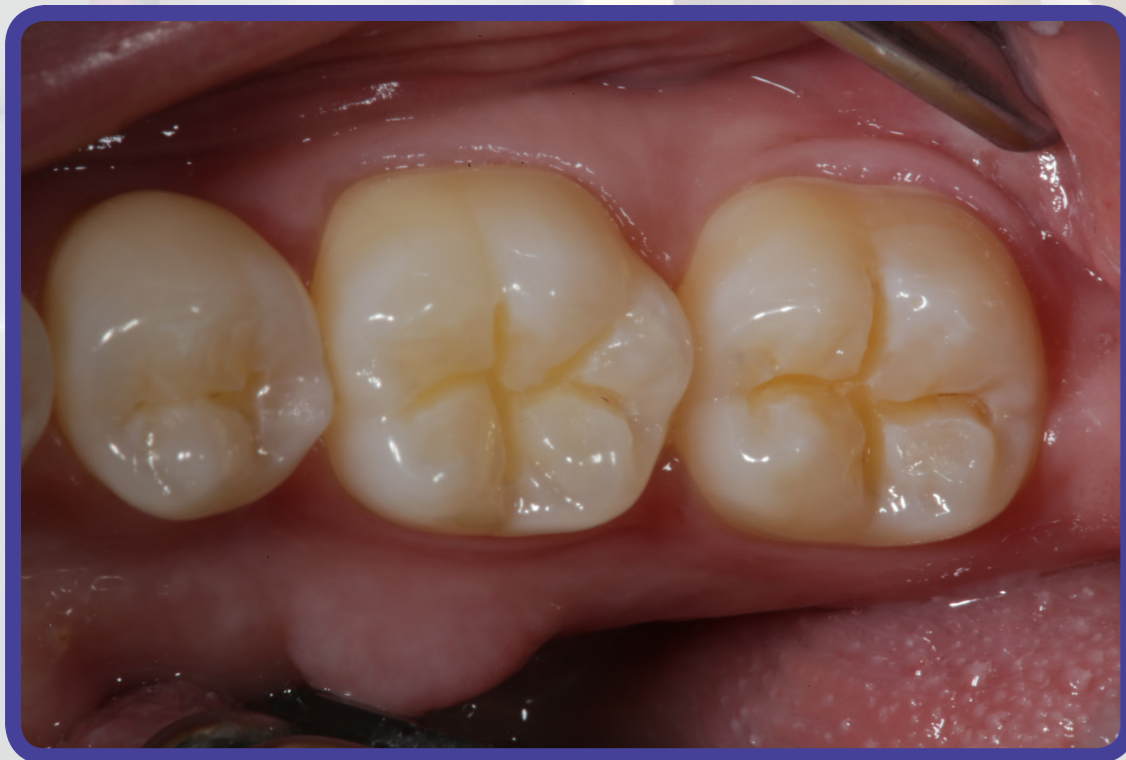

Fig 1. Micro preparation of pits and grooves using a fissurotomy bur (SS White).

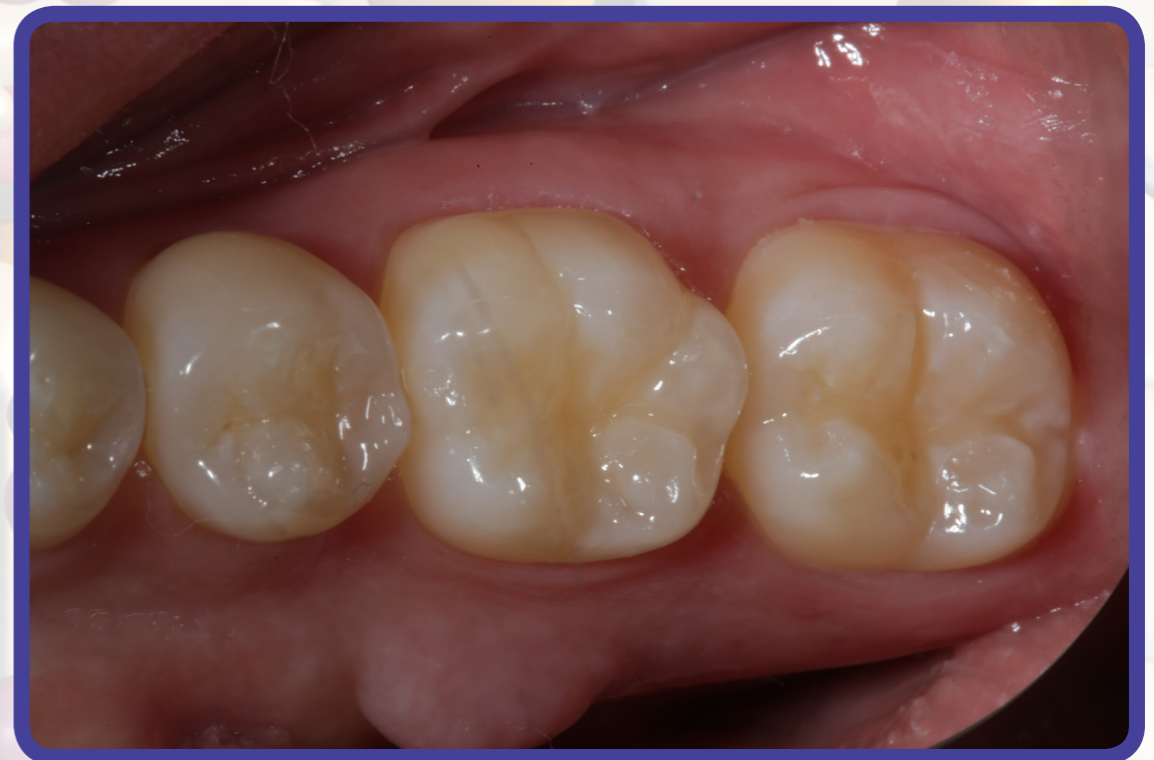

Fig 2. Final restoration.

Class II Restorations

Cavity preparation for **ACTIVA BioACTIVE-RESTORATIVE** is similar to that for conventional composite materials (Figure 3 and Figure 4). Placement is easy using the automix syringe and dispensing cannula (the latter can be bent to an appropriate angle for ease of delivery). A total etch or selective etch protocol and an adhesive bonding agent can be used.

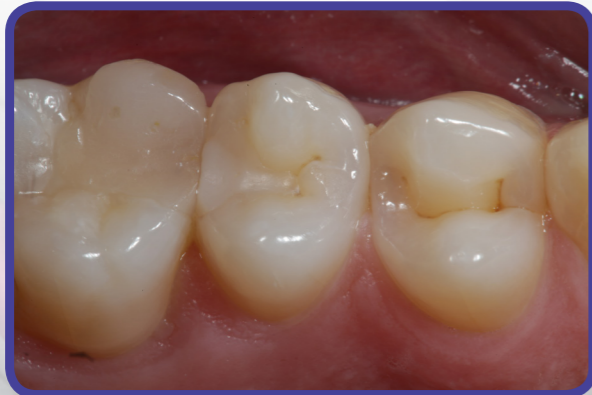

Fig 3. A preoperative occlusal view of tooth No. 4 which has an existing DO composite with recurrent decay and tooth No. 5 with occlusal pit and fissure decay.

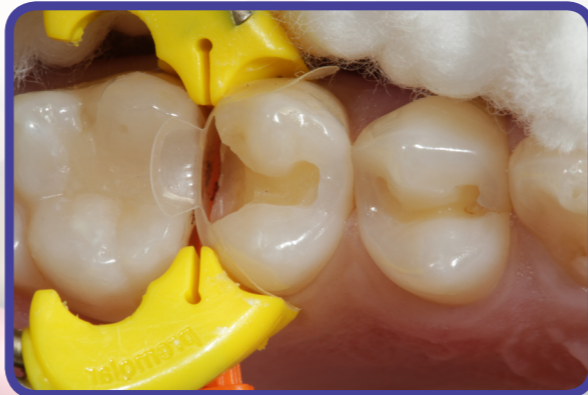

Fig 4. Cavity preparations for tooth No. 4 DO is made using a carbide # 330 (SS White) and tooth No. 5 using a fissurotomy bur (SS White).

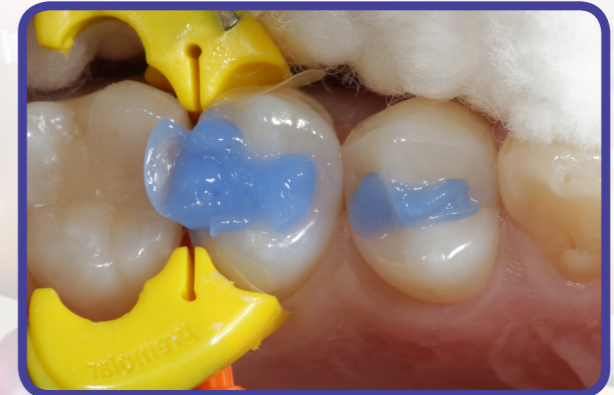

Fig 5. Total etch protocol for 15 seconds, then thoroughly rinsed with water.

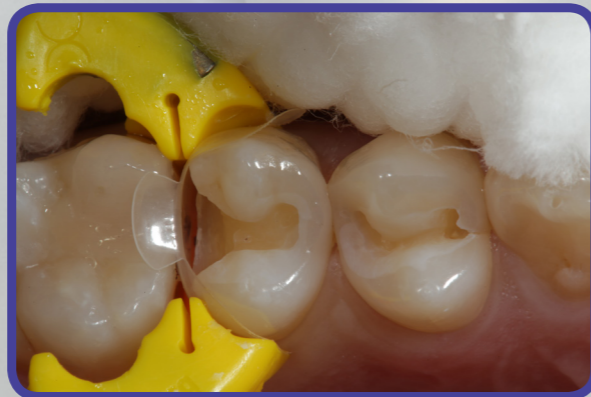

Fig 6. An occlusal view after etching and drying the preparations.

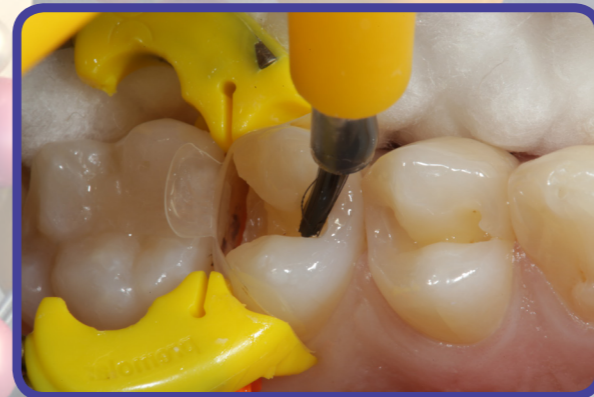

Fig 7. Placement of an adhesive resin on all preparation surfaces is shown.

continued on
next page

Class II Placement

The viscosity of **ACTIVA** is similar to heavy-bodied flowable resins and will adapt well to the internal geometry of any cavity preparation. A sectional matrix system is recommended for Class II placement to limit the material to the preparation and avoid proximal excess. Anatomic detail can be obtained by using rotary instrumentation. A narrow “bullet type” 20 fluted finishing carbide (SS White) is recommended to carve precise anatomic detail.

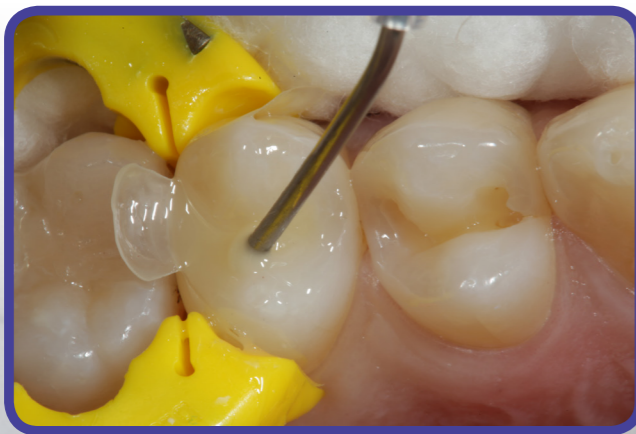

Fig 8. ACTIVA BioACTIVE-RESTORATIVE is dispensed into the cavity preparation of tooth No. 4. The sectional matrix (Biofit, Bioclear) confines the restorative material precisely to the cavity preparation.

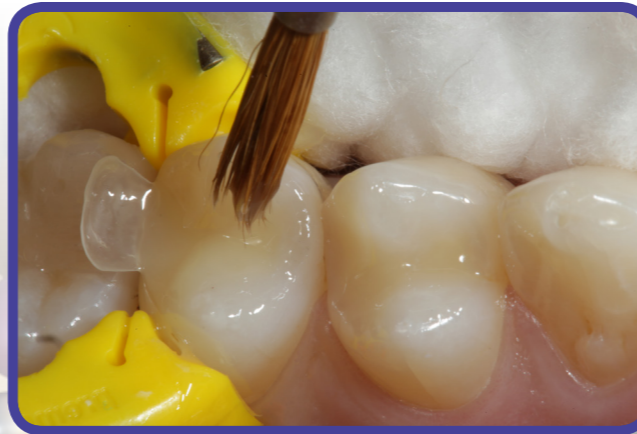

Fig 9. A sable artist's brush is used to adapt the restorative material to the cavity margins and remove excess material prior to light curing. Note: ACTIVA BioACTIVE-RESTORATIVE is a dual cure material.

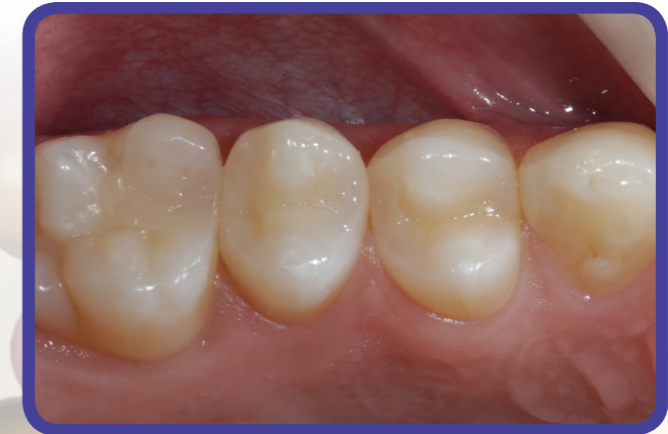

Fig 10. An occlusal view of the completed ACTIVA restorations on teeth Nos. 4 and 5.

Root Caries Restoration

ACTIVA BioACTIVE-RESTORATIVE can be used 1) to restore root caries on exposed root surfaces where gingival recession is present, and 2) below existing full coverage restorations where access is not an issue. Minor surface finishing is accomplished with a composite carbide finishing bur (ET3, Komet USA), followed by use of fine rubber abrasives to gain a final surface finish. A postoperative photograph shows the final result after restoring the root surface decay. At future recall appointments, fluoride varnish is applied to recharge the **ACTIVA BioACTIVE-RESTORATIVE** material to help protect the root surfaces and restorative margins from a recurrence of root caries.

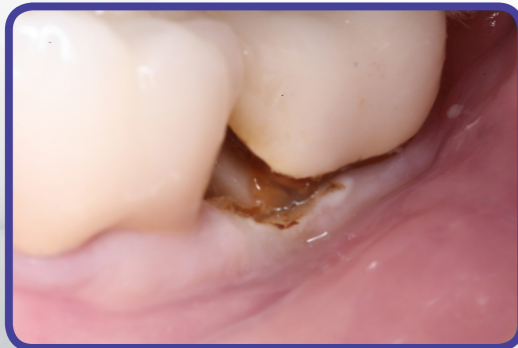

Fig 11. Root caries was found at recall examination on the facial surface of tooth No. 18 below the crown margin. A diode laser was used to gain access for evaluation and potential restoration.

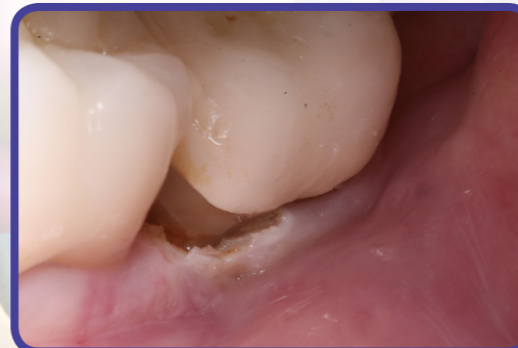

Fig 12. After removal of the decay, the cavity was restored using ACTIVA BioACTIVE-RESTORATIVE material.

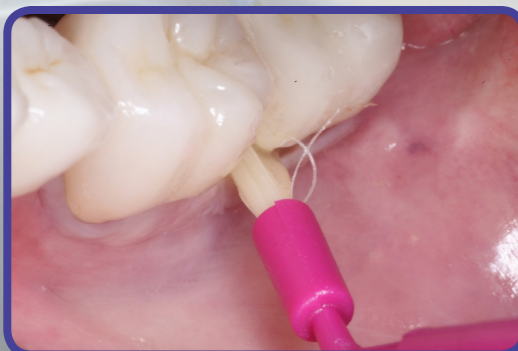

Fig 13. Fluoride varnish is applied at recall appointment (Embrace Varnish, Pulpdent Corporation).

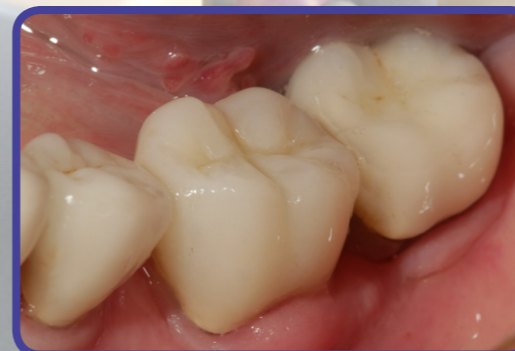

Fig 14. A two year postoperative view of the ACTIVA BioACTIVE-RESTORATIVE root caries restoration on the facial aspect of tooth No. 18.

According to the manufacturer, **ACTIVA BioACTIVE-RESTORATIVE** is the first dental resin that mimics the physical *and* chemical properties of teeth. It contains three key components: 1) Bioactive ionic resin matrix. 2) Shock absorbing rubberized resin component, and 3) Reactive glass ionomers fillers.

Pediatric and Geriatric Applications

ACTIVA BioACTIVE-RESTORATIVE addresses many of the challenges typically associated with the treatment of dental caries in pediatric patients.

Traditional Challenge	Bioactive Solution
Moisture Removal: Traditional composite restoratives require a moisture-free environment for optimal placement.	Bioactive restorative materials are moisture-friendly and do not require a completely dry field.
Patient Management: Complex restorative procedures can be difficult to complete as children may not be cooperative.	ACTIVA BioACTIVE-RESTORATIVE's easy delivery system helps simplify restorative procedures.
Inadequate Home Care: Pediatric patients are not always fastidious about plaque removal and may experience recurrent decay.	Bioactive restoratives elicit a natural response that seals the tooth and restoration, helping to prevent microleakage.

Some of the challenges listed above exist in the **geriatric population** as well. In addition, the decrease in quality and quantity of saliva may make older patients more susceptible to recurrent caries. Bioactive restoratives like **ACTIVA** can help protect these patients' dentition by releasing and recharging essential minerals.

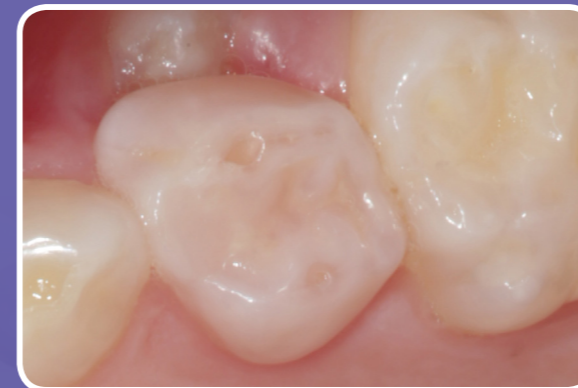

Fig 15. A postoperative occlusal view of an MO ACTIVA restoration on primary tooth No. 1. Tooth No. 12 is seen about to erupt. The patient is only 10 years old, so tooth No. 1 will not exfoliate for a year or more. It is therefore important to maintain tooth 1 restoratively as a space maintainer until tooth No. 12 erupts into the oral cavity.

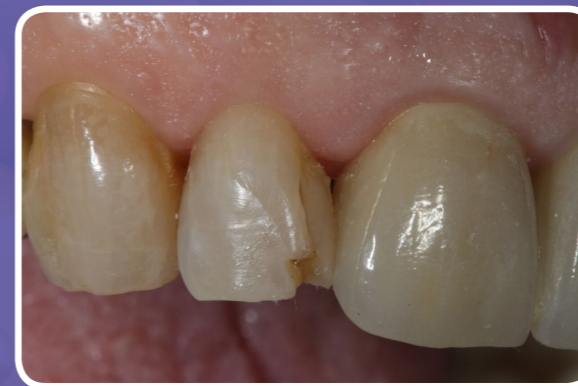

Fig 16. Preoperative view of a failing mesio-incisal Class IV composite (tooth No. 7) on a 78-year-old patient. Recurrent decay and marginal leakage are present. Geriatric patients can be more prone to recurrent decay due to decreased salivary production and less effective home care.

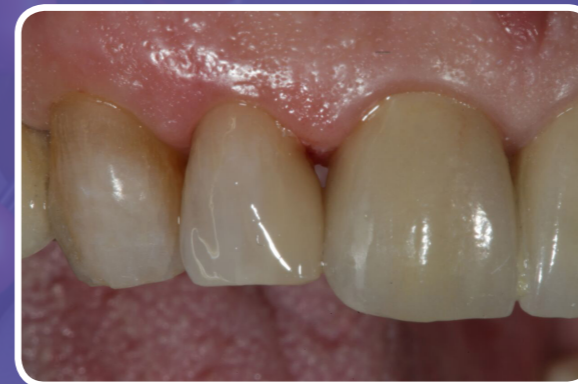

Fig 17. Postoperative view of the mesio-incisal ACTIVA-BIOACTIVE RESTORATIVE restoration on tooth No. 7. A beautifully esthetic result. A bioactive restorative material such as this will provide greater protection than a conventional composite material.

Heroic Dentistry: Saving Failing Restorations

“Heroic” dental procedures are a part of every dental practice. The ideal clinical solution may not be possible for many reasons. A common challenge with the aging population is maintaining patients’ natural teeth as their ability to repel acid challenges in the oral environment declines.

Fig 18. Shows placement of ACTIVA in a sub-marginal preparation on the facial surface of tooth No. 29. Because of the extent of the carious lesion, a full thickness mucoperiosteal flap was elevated to gain access.

Fig 19. The amount and placement of ACTIVA BioACTIVE-RESTORATIVE can be limited to the extent and design of the preparation. The convenience of the unique delivery system provides precise placement in the cavity preparation before curing.

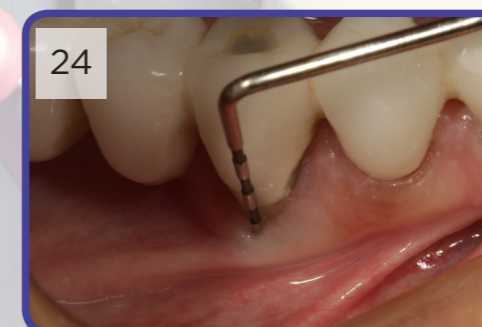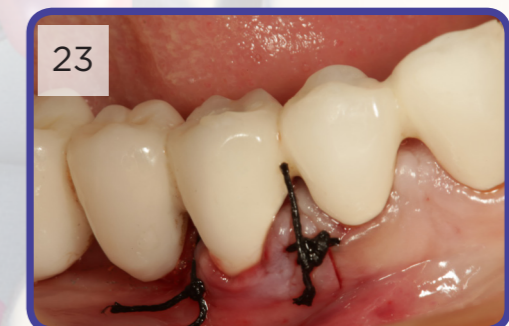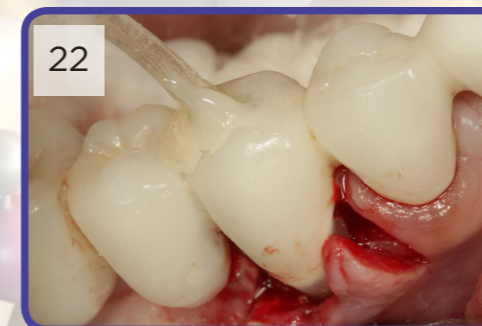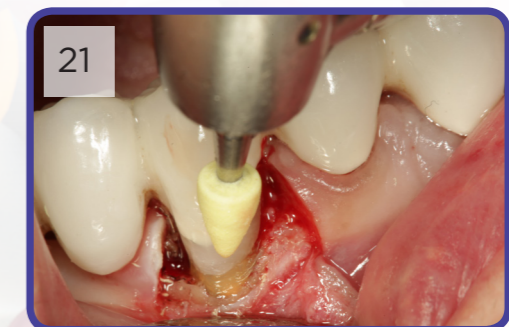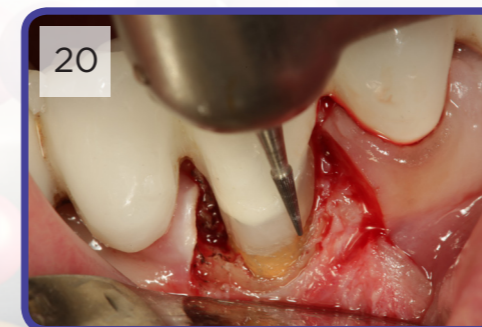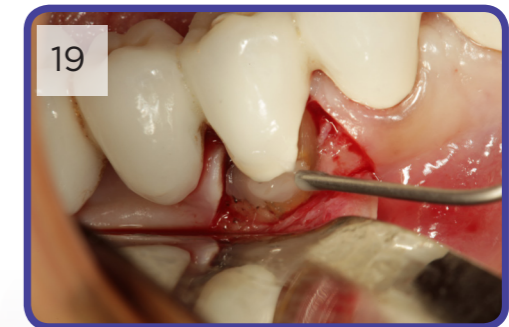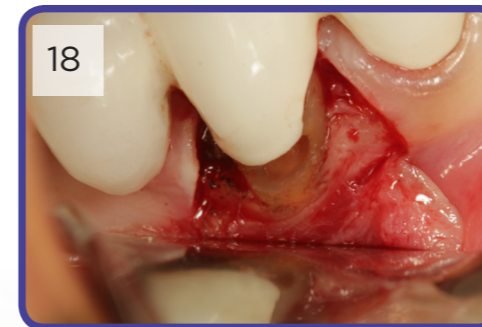Fig 20. The surface of the restorative material is finished with a 30-fluted composite carbide finishing bur (ET 3 UF, Komet USA).

Fig 21. The restoration is polished with a rubber abrasive point (Jiffy Point, Ultradent Products).

Fig 22. ACTIVA BioACTIVE-RESTORATIVE material is used to cement a fiber post (everStick Post, GC America) and to restore the endodontic access cavity in the occlusal surface of the ceramic bridge abutment.

Fig 23. The mucoperiosteal flap is sutured to place and allowed to heal.

Fig 24. Shows a facial view of the restored bridge abutment (tooth No. 29) at 3 years with a perio probe in place measuring a 3-millimeter sulcus with no bleeding. The blanching of the gingival tissue apical to the end of the periodontal probe indicates that attachment has taken place to the ACTIVA BioACTIVE-RESTORATIVE material on the root surface.



Talking to Patients about Bioactive Restoratives

Most patients have a limited understanding of restorative dentistry. As a profession, we have to get better at explaining the disease process of dental caries (decay) and the restorative options that best fit the needs of each patient. Patients need to understand the benefits of early diagnosis and bioactive restorative materials as an integral part of their plan to keep their teeth healthy for a lifetime.

1. Learn about the Patient

When it comes to dental restorations, one size does not fit all. To ensure effective diagnosis and treatment planning, ask questions about dental hygiene, existing restorations, and frequency of dental appointments.

2. Review the Basics of Tooth Biology and Dental Decay

Start by reviewing the basics of tooth biology and the disease process of dental caries. Explain that, like bones, teeth are made of minerals, specifically calcium and phosphate. The bacteria in our mouths feed on sugars, release acids, and cause teeth to lose essential minerals. This is the beginning of tooth decay.

3. Diagnose Early

Talk to patients about the benefits of early diagnosis and conservative restorative options that can help them keep their dentition healthy into their advanced years. Bioactive restorative materials that support the natural remineralization process can help preserve existing tooth structure.

4. Share the Benefits of Bioactivity

Explain how bioactive restorative materials release and recharge essential minerals that help rebuild and protect teeth from acid attack. Rather than merely filling up space, these materials interact and integrate with tooth structure, creating a seal between the material and the tooth.

About the Author



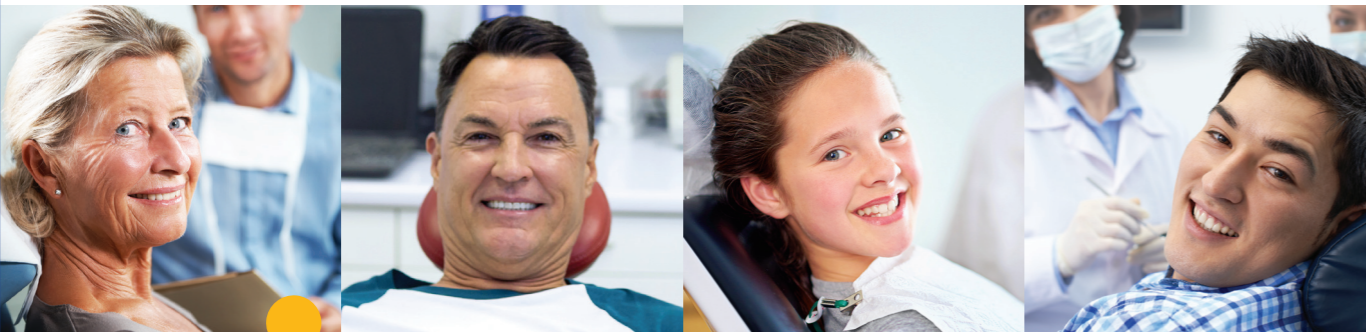Robert A. Lowe, DDS, received his Doctor of Dental Surgery degree from Loyola University School of Dentistry. After completing his residency, Dr. Lowe went into private practice and began to pursue another passion: clinical teaching. While running his own practice, Dr. Lowe served as a Clinical Professor in Restorative Dentistry at Loyola University School of Dentistry until its closure in 1993. In 2000, he relocated to Charlotte, NC.

The preceding material was provided by the manufacturer. Statements and opinions are solely those of the manufacturer and not of the editors, publisher, or the Editorial Board of *Inside Dentistry*.

Inside
Dentistry

EBOOKS

THANK YOU TO OUR SPONSOR: PULPDENT



PULPDENT[®]
DENTAL INNOVATION SINCE 1947

A Composite for Every Generation

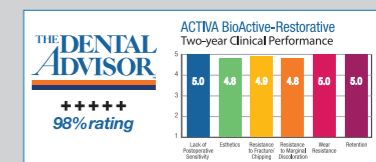
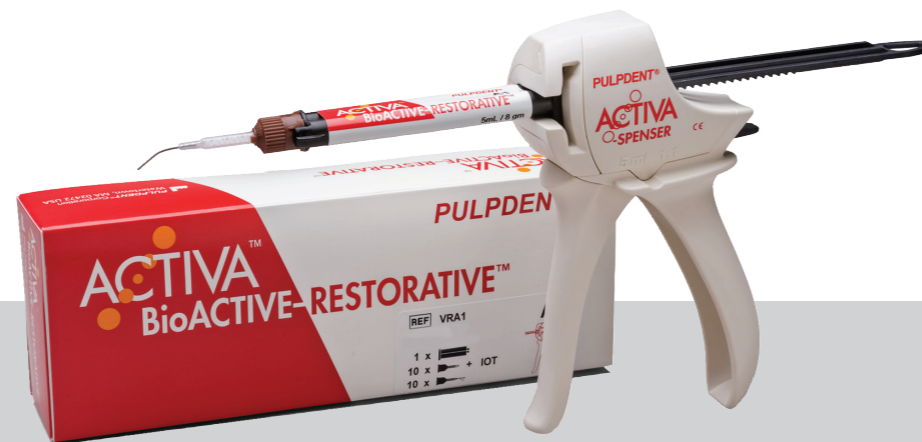BioACTIVE For Better Patient Outcomes:

- Provides the minerals teeth need to stay healthy
- Seals out microleakage
- Remarkably esthetic and versatile
- Tough, durable, and reliable

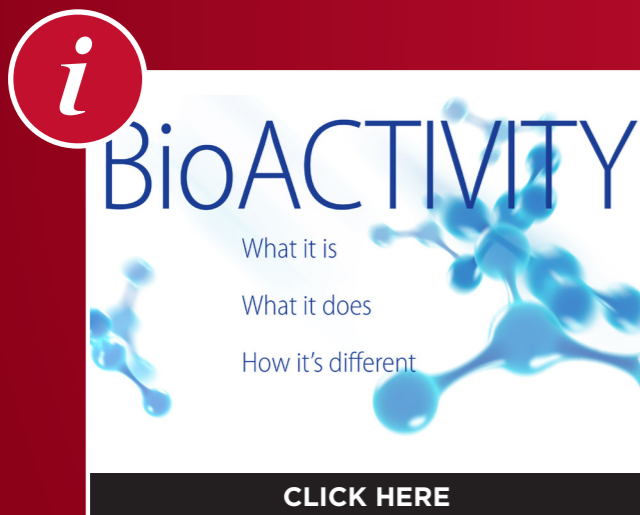#ACTIVABioACTIVE

Learn more at Pulpdent.com/ACTIVA

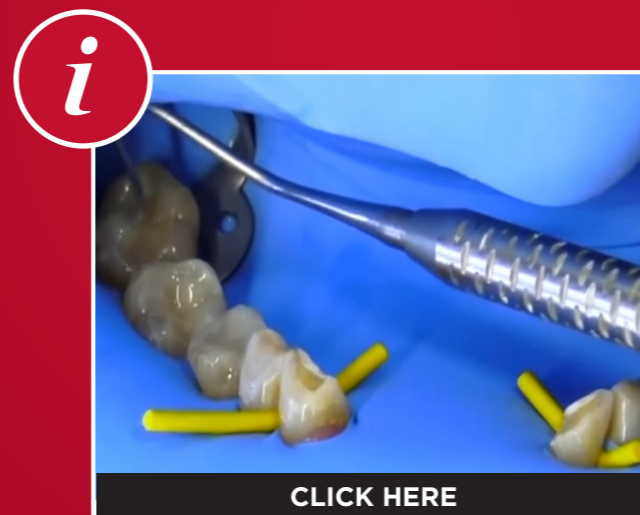ACTIVA[™]
BioACTIVE



ADDITIONAL RESOURCES



Download the BioACTIVE
Brochure



Watch: 9 ACTIVA Restorations
in 1 Appointment



Download the White Paper